

CASE REPORT

Beyond appearances: blepharo-cheilo-dontic syndrome. First case in Ecuador

Paola Vélez

Pediatrician, Homero Castanier Crespo Hospital, Azogues, Ecuador

**Open access****Correspondence to**

Paola Vélez
Luis Manuel Gonzalez and
Andres F Cordova, Azogues
Phone +593 995598843
Email piovp@yahoo.com.mx

Competing interest

None declared

Received: July 25, 2016

Accepted: November 3, 2016

Informed consent

Informed consent form was duly signed by the parents of the patient regarding acceptance for investigation and publication

@ 2016 Vélez P. Open access article distributed under the terms of CC BY-NC-ND



The Rare Diseases and Orphan Drugs Journal has received funding from the European Union Seventh Framework Programme (FP7/2007-2013) under Grant Agreement n. 305690 RARE-Bestpractices project www.rarebestpractices.eu. Sole responsibility lies with the authors and the European Commission is not responsible for any use that may be made of the information contained therein.

Abstract

Blepharo-cheilo-dontic (BCD) syndrome comprises the combination of lagophthalmia, euryblepharon, lower eyelid ectropion, distichiasis, cleft lip and palate and oligodontia. This combination has been described as an autosomal dominant condition with variable expression. We herein described an Ecuadorian girl with consistent signs of BCD syndrome. Our patient also has unilateral hearing loss and metatarsus varus. The aim of this paper is to add this case of blepharo-cheilo-dontic syndrome to world casuistry, as it is considered a rare disease.

Key words

Blepharo-cheilo-dontic, cleft lip and palate, euryblepharon, lagophthalmia, ectropion, distichiasis, unilateral hearing loss, metatarsus varus.

Introduction

Rare diseases have a low prevalence in populations. In Europe, a disease is considered rare when it affects 1 in 2,000 people (Eurordis). Rare diseases are characterized by a wide variety of disorders and symptoms that vary not only by disease, but also among patients suffering from the same disease. Research and patient registration is especially essential in making these diseases visible; in many cases, these diseases have been forgotten and may even be completely unknown to most doctors. Blepharo-cheilo-dontic syndrome is an ultra-rare syndrome, with a total of 50 cases reported, as stated by agencies such as Orphanet [1]. The aim of our publication is to add this case of blepharo-cheilo-dontic syndrome to the world casuistry so that it may be considered a rare disease, and it also seeks encouraging physicians to report this type of pathology.

Clinical case

Female newborn, normal birth, with appropriate weight for her gestational age, weight: 2560g, size: 51cm, chest circumference: 31cm, head circumference: 33cm, Apgar 8-9, Capurro 38 weeks of gestation. Physical examination highlights: broad forehead, broad nasal bridge, hypertelorism, ectropion, lagophthalmos, euryblepharon, low-set ears, complete cleft palate (soft and hard), bilateral cleft lip. (Figure 1).

Mother is a 34-year-old housewife from the countryside. Pregnancies: 4, abortions: 1 (third pregnancy, 10 weeks); births: 2, C-section: 1. During this pregnancy, the mother presents: poor weight gain, fetal ultrasound reports low weight, no history of exposure to toxic agents. Father is 37 years old. No consanguinity. No other member of the family has been affected by this disease.

The patient was admitted in the Neonatology Unit for food support, and was discharged without complications within 4 days. The newborn was fed exclusively breast milk. At 8 months old, the patient shows signs of potential hearing loss. At 10 months old, the patient underwent a Millard Repair in order to correct her cleft lip and palate (Figure 2). At 13 months old, traumatology reports show metatarsus varus. The oph-

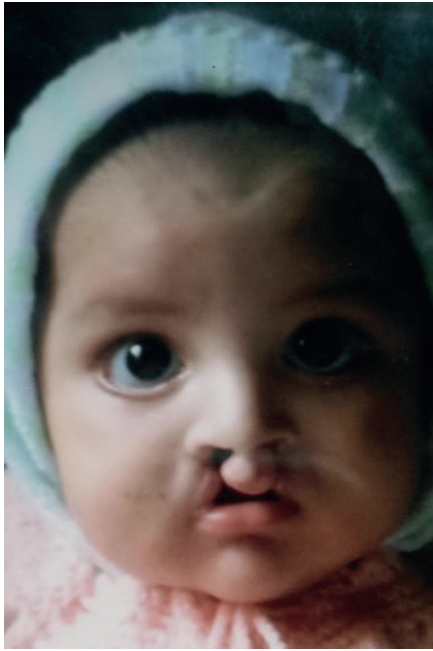


Figure 1. Three months old: euryblepharon and bilateral cleft lip can be identified (with permission from her parents).

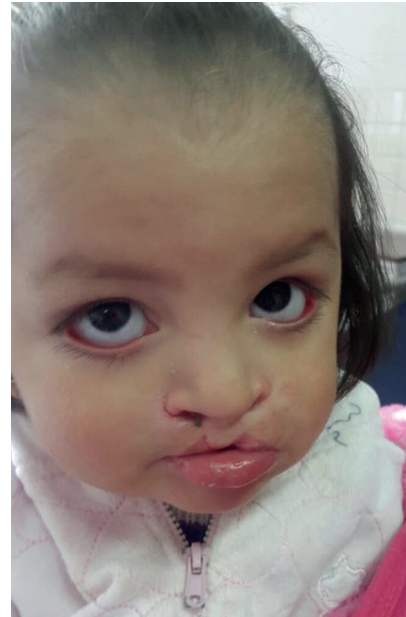

Figure 2. One year old: cleft lip and palate have been corrected. Lagophthalmos is notorious for increasing the euryblepharon (with permission from her parents).

thalmologist recommends artificial tears to prevent corneal laceration (Figure 2).

The patient is currently 18 months old and has been admitted to the pediatrics service multiple times with respiratory infections; last hospitalization was for pneumonia caused by AH1N1, with no complications. It is noted that the patient's teeth are emergent and conical. A comprehensive assessment allowed determining that the clinical manifestations the patient shows are consistent with blepharo-cheilo-dontic syndrome, which was then verified with a genetic analysis, with a normal karyotype.

Discussion

Blepharo-cheilo-dontic syndrome (BCD) (OMIM # 119580) [2] is characterized by the combination of symptoms involving the eyelids, lips and teeth. Blepharo-cheilo-dontic syndrome is a rare autosomal, congenital and dominant condition that includes facial clefting, oligodontia, euryblepharon, lagophthalmos and ectropion [3].

Elschnig (1912) described an association of lower eyelid ectropion, hypertelorism and cleft lip and palate; however, Gorlin et al proposed the term BCD in 1996, though the disease was initially known under the eponym 'Elschnig syndrome'. BCD syndrome has been described in many combinations or included in others such as Miller syndrome, Genée-Wiedemann syndrome or Warburg syndrome [3]. As of 2006, only 32 cases of BCD syndrome have been reported worldwide; in Latin America, Mexico and Brazil are the only two countries with reported cases [4].

From the literature review, it was found that there was no gender predilection in terms of this syndrome [4]. Different combinations of these signs have been found sporadically, with 100% penetration autosomal dominant inheritance [5]. In view of the rarity of the condition, the clinical spectrum is still being delineated and the etiology remains unknown; in our case, the patient was not exposed to toxic agents and did not have a family history of malformations [6].

After considering the clinical similarities between the BCD syndrome and other conditions with ectodermal defects and oral clefts, many observations suggest that mutations in gene p63 and interferon regulatory factor 6 (IRF6) could be implicated as potential candidate genes for BCD syndrome [7].

Other cases with congenital thyroid agenesis and typical findings of BCD syndrome extended the discussion about the genes involved in this syndrome's causes to include thyroid transcription factor 2 (TTF-2 or FOXE1). In humans, one case of a missense mutation in FOXE1 has been found in a case of isolated cleft lip and palate. Recently, two other candidate genes for BCD were described: the odd-skipped-related 2A protein (OSR2) and the T-box-containing protein 10 (TBX10). These genes encode a zinc-finger protein that exhibits a dynamic expression pattern during craniofacial development, primarily in the developing palate and teeth [6].

More recent studies focus on the importance of gene *Dlx4*. In mammals, there are three *Dlx* homeobox clusters with closely located gene pairs (*Dlx1/Dlx2*, *Dlx3/*

Dlx4, Dlx5/Dlx6). In situ hybridization showed that Dlx4 is expressed in the mesenchyme of the murine palatal shelves at E12.5, prior to palate closure. From the published literature, Dlx1/Dlx2 double homozygous null mice and Dlx5 homozygous null mice both presented clefts in the secondary palate. A DLX4 mutation in a family with cleft lip and palate establishes DLX4 as a potential cause of human clefts [8].

Patients with autosomal dominant blepharo-cheilo-dontic (BCD) syndrome have mainly eye, dental and limb anomalies [9].

Eye anomalies include: lower lid ectropion, distichiasis of the upper eyelids, euryblepharon, hypertelorism and lagophthalmia [3]. Upper eyelid distichiasis is the presence of a double row of eyelashes. Lagophthalmia is a condition in which the eye cannot be completely closed because the palpebral fissures are wider than normal [2]. Euryblepharon suggests that once the eyelid is everted in the uterus, for some reason, orbicularis spasms act as a sphincter that leads to secondary venous engorgement and chemosis; until this cycle is broken, the eyelid will not assume its normal position [10]. Our patient was born with mild eye abnormalities, but these increased with facial growth.

Oral anomalies include cleft lip and palate (most often bilateral), conical teeth, hypodontia, oligodontia and/or microdontia. Oligodontia has been found in three quarters of the cases reported, whereas conical teeth have been noted in less than half [2]. The sites of missing teeth in mild oligodontia cases were adjacent to the cleft of the lip. Micro-retrognathia was reported in 5 cases [4].

Other sporadic symptoms that have been reported in patients with this disorder include clinodactyly, syndactyly [7, 9], hypothyroidism, imperforate anus [11] and hearing loss [6], as reported in our case, though there have been some cases of BCD syndrome with dermal symptoms such as sparse scalp hair and hypoplastic nails [4]. However, no cases for BCD syndrome have been reported with metatarsus varus or joint deformities, as is the case of this patient.

No individual had potentially fatal symptoms. Growth and development were normal in all reported patients [4]. The clinical manifestations in our patient are similar to other cases of BCD reported in literature, presenting normal physical and intellectual development.

Treatment should be comprehensive, focused on repairing facial deformities with proper functionality [12].

For ocular deformities, lateral tarsal strip repairs, eyelid retraction and lateral tarsorrhaphy were performed. Appropriate reconstructive surgery of the eyelids reduces the morbidity associated with eyelid anomalies and provides an excellent cosmetic result for patients with blepharo-cheilo-dontic syndrome [13]. Removal of the horizontal laxity of the eyelid is needed for managing ectropion; however, vertical shortage of the eyelid remains and lagophthalmos never disappears [10].

The use of overdentures, a conservative approach for

cases of severe maxillary hypoplasia, severe hypodontia and cleft lip and palate, is well documented. Overdentures can readily restore function, appearance, soft tissue deficit and re-establish positive occlusion, as the prostheses replace both the tissue and missing teeth, increase vertical facial height and result in an overall improvement in appearance [12].

Conclusions

All typical symptoms of blepharo-cheilo-dontic syndrome such as euryblepharon, lower eyelid ectropion, bilateral cleft lip and palate, and conical teeth were observed in our patient. For this patient, this study recommends a long and active treatment plan with a multi-disciplinary team that may address all areas of development.

References

1. Informes Periódicos de Orphanet. Prevalence of rare diseases: Bibliographic data. Marzo 2016. Número 2. http://www.orpha.net/orphacom/cahiers/docs/ES/Prevalencia_de_las_enfermedades_raras_por_prevalencia_decreciente_o_casos.pdf
2. Ababneh K, Al-Swaid A, Elhag A, Youssef T, Alsaif S. Blepharo-cheilo-dontic (BCD) syndrome: expanding the phenotype, case report and review of literature. *Am J Med Genet A* 2014;164A(6):1525-9. doi: 10.1002/ajmg.a.36465. Epub 2014 Apr 9.
3. Gorlin R, Zellweger H, Curtis M et al. Blepharo-cheilo-dontic (BCD) syndrome. *Am J Med Genet* 1996;65(2):109-12.
4. Iida A, Narai S, Takagi R, Ono K, Ikeda N. Blepharo-cheilo-dontic (BCD) syndrome: case report. *Cleft Palate Craniofac J* 2006;43(2):237-43.
5. Valdéz-de la Torre M, Quintana-García M, Canún S. Blepharo-cheilo-dontic (BCD) syndrome in two Mexican patients. *Am J Med Genet* 1999;85(2):157-9.
6. Freitas E, Martinhago C, Ramos S, Murray J, Gil-da-Silva-Lopes V. Preliminary molecular studies on blepharocheilodontic syndrome. *Am J Med Genet* 2007;143(A):2757-59.
7. Gil-da-Silva-Lopes V, Guion-Almeida M, De Oliveira Rodini E. Blepharocheilodontic (BCD) syndrome: expanding the phenotype? *Am J Med Genet* 2003;121(A):266-270.
8. Wu D, Mandal S, Choi A, et al. DLX4 is associated with orofacial clefting and abnormal jaw development. *Hum Mol Genet* 2015;24(15):4340-52. doi: 10.1093/hmg/ddv167. Epub 2015 May 7.
9. Navasheillaretna R, Sockalingam S. Clinical manifestation of blepharocheilodontic (BCD) syndrome: a case review. *Sains Malaysiana* 2013;42(1):85-88.
10. Miyamoto T, Nakajima T, Nagasao T, Shimada T. Blepharocheilodontic syndrome: surgical. Management of euryblepharon and nocturnal eyelid eversion. *Plast Reconstr Surg* 2004; 114(1):138-41. doi:10.1097/01.PRS.0000129076.34336.49
11. Weaver K, Rutledge K, Grant J, Robin N. Imperforate anus is a rare associated finding in blepharocheilodontic syndrome. *Am J Med Genet A* 2010;152A(2):438-40. doi: 10.1002/ajmg.a.33207
12. Adeboye S, Cole B, Jepson N, Hodgkinson P. Multidisciplinary management of blepharo-cheilo-dontic syndrome and the role of overdenture in dental management. *Eur J Paediatr Dent* 2009;10(4):201-4.
13. Yen M, Lucci L, Anderson R. Management of eyelid anomalies associated with Blepharo-cheilo-dontic syndrome. *Am J Ophthalmol* 2001;132(2):279-80.